



Morphometric study of the Acetabulum in Human hip bones: An anatomical analysis

1. Archana Narasipuram, Associate Professor, Apollo Institute of Medical sciences and Research, Hyderabad.

Co author: .Archana Narasipuram, Associate Professor, Apollo Institute of Medical sciences and Research, Hyderabad

2. Jasmeen sheikh Vajir, Professor and HOD, Apollo Institute of Medical sciences and Research, Hyderabad.

Abstract

Background: Hip bone is an irregular shaped bone formed by the union of ilium, ischium and pubis. The acetabulum is a deep cup shaped cavity present on the lateral side of the hip bone . It has a smooth lunate articular surface that articulates with the head of the femur to form the hip joint, a rough non articular part acetabular fossa and acetabular notch. Morphometry of acetabular fossa forms the basis for construction of prosthesis of acetabulum.

Objective: To study the morphology of acetabulum margins, to measure the various dimensions of the acetabulum in dry human hip bone.

Material and methods: The present study was a descriptive observational study conducted in the department of Anatomy at Apollo Institute of Medical Sciences and Research, Hyderabad. 100 Human hip bones of both sexes were used. Hip bones with any evidence of trauma were excluded. Shape of the anterior margin of acetabulum was noted. Transverse diameter, vertical diameter of the acetabulum and width of the acetabular notch was measured using vernier callipers. Data was collected and compiled using Microsoft Excel, analyzed using SPSS software. Frequency, Mean and standard deviation was calculated.

Results: Most common shape of the acetabulum was curved followed by straight, irregular. Mean transverse diameter was 46.8 mm. Mean vertical diameter was 47.23mm.

Conclusion: Knowledge of morphometry of anterior acetabular ridge is very important for total hip arthroplasty. Knowledge of dimension of the acetabulum is vital for biomedical engineers as it guides the design and customization of prosthetic components for hip replacement surgeries. This morphometric exploration not only enhances our understanding of normal hip anatomy but also holds significant relevance in guiding clinical decisions and interventions.

Key words: Acetabulum, Morphometry, Arthroplasty.

Introduction:

- The acetabulum is a crucial anatomical structure of the hip joint, playing a significant role in hip stability and function . It has a smooth lunate articular surface covered by hyaline cartilage and a rough non articular part called the acetabular fossa filled with fibroblastic fat .The articular surface is deficient inferiorly, known as acetabular notch and is bridged by the transverse



acetabular ligament¹. A fibrocartilagenous rim known as acetabular labrum increases the depth of the acetabulum. It holds the femoral head and provide stability to the hip joint.

Development of normal acetabular cavity is essential for proper biomechanism of hip joint.

Cavity starts developing from 5th to 6th week of intrauterinelife. During 7th week of gestation, precartilagenous pattern is seen and entire acetabulum is fully formed at 8th week of foetus².

Displacement of hip joint occurs when the normal relationship between the femur and acetabulum is disrupted. Understanding its morphometry is essential for diagnosing and managing various hip pathologies. This paper aims to present a review of the morphometric characteristics of the acetabulum and discuss their clinical implications. By analyzing the dimensions and variations of the acetabulum, clinicians and orthopedic surgeons can improve preoperative planning, implant selection, and surgical outcomes for hip-related procedures

- **Objective:** To study the morphology of acetabular margin and to measure the various dimensions of the acetabulum in dry human hip bone .
- **Material and methods:** Descriptive observational study conducted in the Department of Anatomy at Apollo Institute of Medical Sciences and Research,Hyderabad .100 Human hip bones of both sexes were used. Exclusion criteria: Hip bones with evidence of damage were excluded. Osteometric parameters like vertical, Transverse, Anteroposterior diameter and depth of the acetabulum was measured using vernier callipers, metallic scale. Shape of the anterior acetabular ridge were noted. The following parameters were observed.
 1. Shape of the acetabulum-curved, angular, irregular, straight
 2. Transverse diameter of the acetabulum-farthest distance on acetabular rim in horizontal plane
 3. Anteroposterior diameter-farthest distance on the acetabular rim in anteroposterior axis
 4. Vertical diameter-the greatest diameter between the upper and lower margins of the acetabular cavity
 - 5 .Depth of the acetabulum-A thin metallic scale was placed across the acetabulum and depth of the acetabulum was measured.

- **Results:** In our study, we found the most common shape of acetabulum was curved.

Fig-2 showing the mean transverse diameter of acetabulum on right and left side.

Mean transverse diameter is 4.43 cm+/-0.3 on left side,4.50+/-0.41 on right side

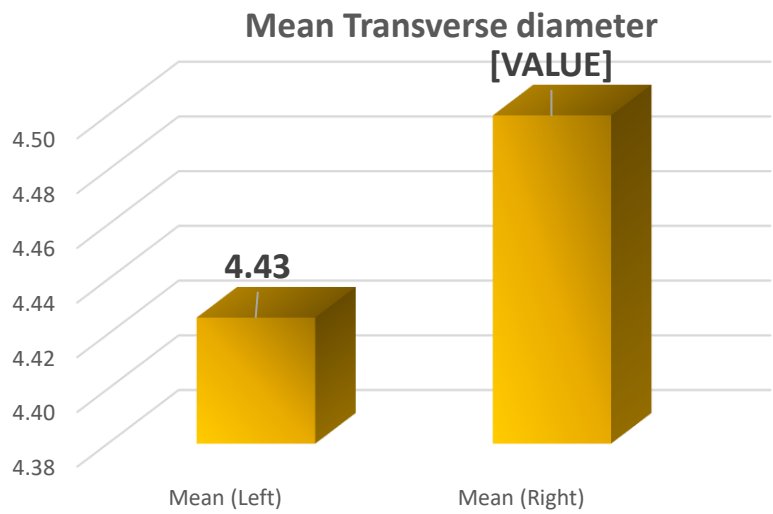
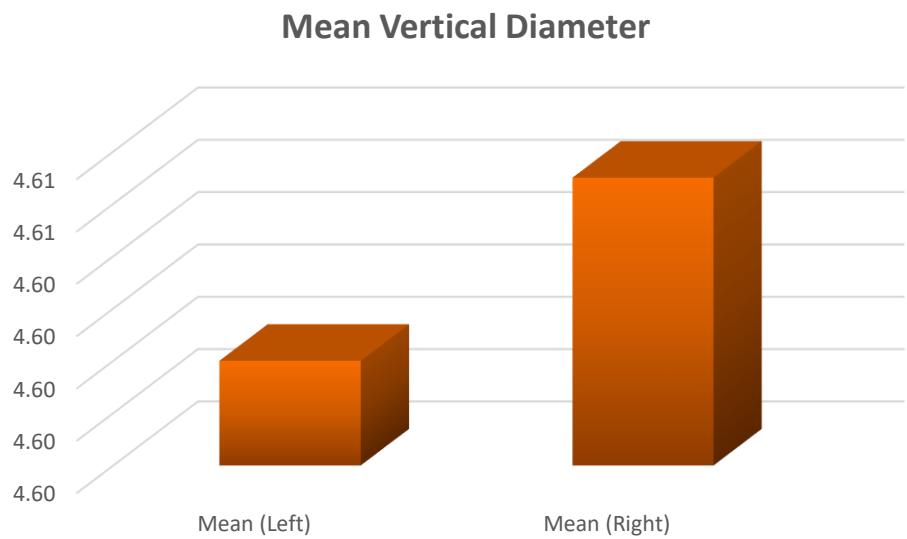
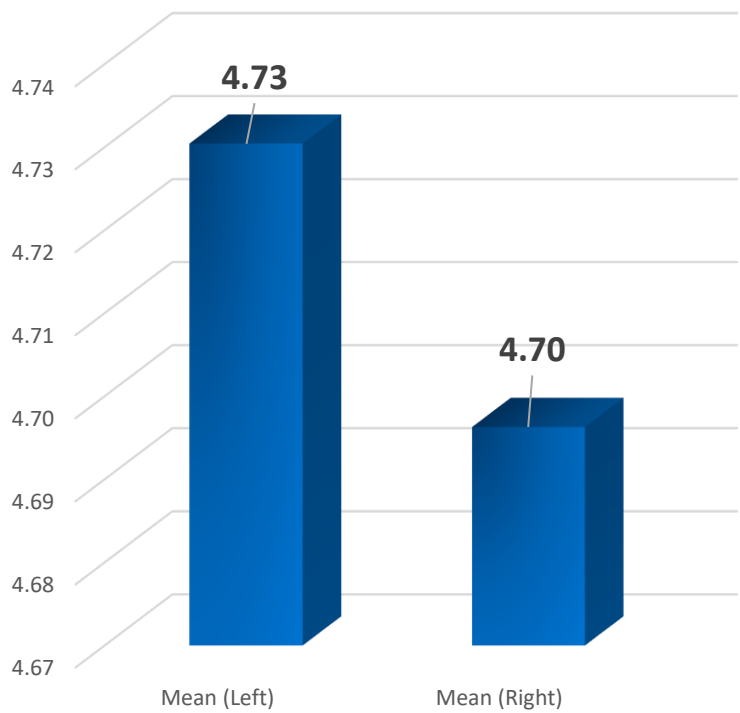


Fig-3 showing the mean vertical diameter of the acetabulum right and left side

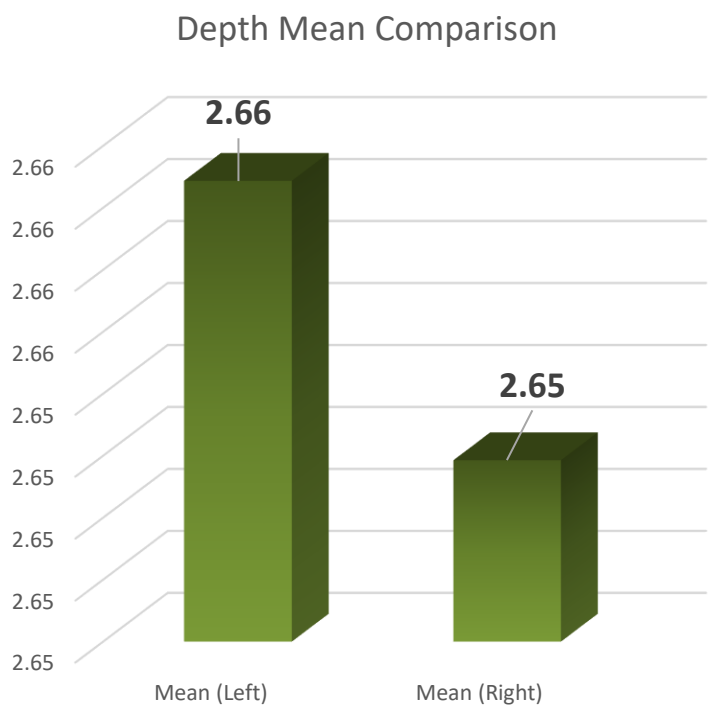
Mean vertical diameter on left side is 4.56cm+/- 0.38 and 4.61+/-0.47



- Fig-4 showing mean Ap diameter- Mean Ap diameter on the left side is 4.73cm+/-0.34 and right side is 4.70cm+/-0.39



• Fig-5 showing mean depth Mean depth on the left side is 2.66 cm+/-0.4 and right side is 2.5cm+/-0.4





- **Discussion:** *Hip joint is one of the major joints of the body. Variations in the acetabular dimensions remain a challenge for surgeons during arthroplasty. Various morphometric parameters of acetabulum may assist them to deliver the best results by preferring prosthesis with appropriate dimensions .In our current study, the most common shape was curved which was 56 % , angulated 16%,straight 16% irregular 12%.compared to previous studies by Mridul Tripathi et al,curved shape was observed in 50% followed by 30%,5%15% similar with our study.Mean transverse diameter was 4.43 cm+/-0.3 on left side,4.50+/-0.41 on right side which was similar to the study by InaBahl 4.72 cm.In the present study,Mean vertical diameter on left side is 4.56cm+/- 0.38 and on the right 4.61+/-0.47 compared with the study by Archana singh et al 4.83+/-3.12 and 4.8+/-3.5 .Mean depth on the left side is 2.66+/-0.41 and on the right side is 2.65+/-0.40 which coincides with the study done by Kintu Vyas et.al 2.65 and 2.71 cm.Values noted by most of the authors are consistent with present study values*

- **Conclusion:**

The insights gained from morphometric analyses directly impact the design of hip prosthetics. Knowledge of dimension of the acetabulum is vital for biomedical engineers as it guides the design and customization of prosthetic components for hip replacement surgeries. This morphometric exploration not only enhances our understanding of normal hip anatomy but also holds significant relevance in guiding clinical decisions and interventions .Customizing implants to match individual acetabular dimensions improves implant longevity, stability, and overall patient satisfaction.

References:

1. Standring S.Grays Anatomy.Thirty –ninth Edition.Elsevier Churchill,Livingstone.2005;1421.
2. Bollavaram Pullanna, Gautham Kamble, Jayalakshmi P. V. Study of morphometric analysis of acetabulum and its clinical correlation in South Indian population. Int J Anat Res 2022;10(2):8352-8358. DOI: 10.16965/ijar.2022.125.
3. Singh, Archana; Gupta, Rakesh; Singh, Arun¹. Morphological and Morphometric Study of the Acetabulum of Dry Human Hip Bone and its Clinical Implication in Hip Arthroplasty. Journal of the Anatomical Society of India 69(4):p 220-225, Oct–Dec 2020. | DOI: 10.4103/JASI.JASI_214_19
4. 4.Tripathi, M., & Gajbhiye, V. (2022). Morphometric and Morphology study of acetabulum of human hip bone in Central Indian population. *International Journal of Health Sciences*, 6(S1), 1064–1072. <https://doi.org/10.53730/ijhs.v6nS1.4856>
- 5.IIankathirSridharan,SudagarMuthusamy,RajanThangarasu,etal.Morphometric Study of Acetabulum in Adult DryHuman Pelvic Bone.IndianJAnat.2019;8(4):289–292.



6.Dhindsa, Gursharan Singh. "Acetabulum: a morphometric study." *Journal of Evolution of Medical and Dental Sciences*, vol. 2, no. 7, 18 Feb. 2013, pp. 657

7. JM, Goldsmith CH. Morphometric study of the fetal development of the human hip joint: significance for congenital hip disease. *Yale J Biol Med*. 1981 Nov-Dec;54(6):411-37. PMID: 7342490; PMCID: PMC2596054.

8.Nayak, Gyanaranjan. (2017). AN ANATOMICAL STUDY OF DIMENSIONS OF ACETABULUM IN AN EASTERN INDIAN POPULATION. *International Journal of Anatomy and Research*. 2017. 4173-76. 10.16965/ijar.2017.276.